

PEDIATRICS

OFFICIAL JOURNAL OF THE AMERICAN ACADEMY OF PEDIATRICS

Symptomatic Acute Myocarditis in Seven Adolescents Following Pfizer-BioNTech COVID-19 Vaccination

Mayme Marshall, MD, Ian D. Ferguson, MD, Paul Lewis, MD, MPH, Preeti Jaggi, MD, Christina Gagliardo, MD, James Stewart Collins, MD, Robin Shaughnessy, MD, Rachel Caron, BA, Cristina Fuss, MD, Kathleen Jo E. Corbin, MD, MHS, Leonard Emuren, MBBS, PhD, Erin Faherty, MD, E. Kevin Hall, MD, Cecilia Di Pentima, MD, MPH, Matthew E. Oster, MD, MPH, Elijah Paintsil, MD, Saira Siddiqui, MD, Donna M. Timchak, MD, Judith A. Guzman-Cottrill, DO

DOI: 10.1542/peds.2021-052478

Journal: *Pediatrics*

Article Type: Case Report

Citation: Marshall M, Ferguson ID, Lewis P, et al. Symptomatic acute myocarditis in seven adolescents following Pfizer-BioNTech COVID-19 vaccination. *Pediatrics*. 2021; doi: 10.1542/peds.2021-052478

This is a prepublication version of an article that has undergone peer review and been accepted for publication but is not the final version of record. This paper may be cited using the DOI and date of access. This paper may contain information that has errors in facts, figures, and statements, and will be corrected in the final published version. The journal is providing an early version of this article to expedite access to this information. The American Academy of Pediatrics, the editors, and authors are not responsible for inaccurate information and data described in this version.

Symptomatic Acute Myocarditis in Seven Adolescents Following Pfizer-BioNTech COVID-19 Vaccination

Mayme Marshall^a, MD, Ian D. Ferguson^b, MD, Paul Lewis^a, MD, MPH, Preeti Jaggi^c, MD, Christina Gagliardo^{d,e}, MD, James Stewart Collins^f, MD, Robin Shaughnessy^a, MD, Rachel Caron^a, BA, Cristina Fuss^a, MD, Kathleen Jo E. Corbin^b, MD, MHS, Leonard Emuren^b, MBBS, PhD, Erin Faherty^b, MD, E. Kevin Hall^b, MD, Cecilia Di Pentima^{d,e}, MD, MPH, Matthew E. Oster^c, MD, MPH, Elijah Paintsil^b, MD, Saira Siddiqui^d, MD, Donna M. Timchak^{d,g}, MD, Judith A. Guzman-Cottrill^a, DO

Affiliations: ^aOregon Health and Science University School of Medicine, Portland, Oregon; ^bYale University School of Medicine, New Haven, Connecticut; ^cEmory University School of Medicine and Children's Healthcare of Atlanta, Georgia; ^dGoryeb Children's Hospital, Atlantic Health System, Morristown, New Jersey; ^eThomas Jefferson University, Philadelphia, Pennsylvania; ^fSpectrum Health, Grand Rapids, Michigan; ^gColumbia University Irving Medical Center, New York, New York

Address correspondence to: Judith Guzman-Cottrill, Department of Pediatrics, Oregon Health and Science University, 707 SW Gaines Road, mailcode CDRC-P, Portland, OR, 97239, [guzmanco@ohsu.edu], 503-494-3305.

Conflict of Interest Disclosures (includes financial disclosures): All authors have no conflicts of interest to disclose.

Funding/Support: No funding was secured for the preparation or submission of this report.

Abbreviations: Atrioventricular (AV), coronavirus disease 2019 (COVID-19), C-reactive protein (CRP), Centers for Disease Control and Prevention (CDC), electrocardiogram (ECG), Emergency Department (ED), Emergency Use Authorization (EUA), Food and Drug Administration (FDA), intravenous immunoglobulin (IVIG), magnetic resonance imaging (MRI), multisystem inflammatory syndrome in children (MIS-C), non-steroidal anti-inflammatory drug (NSAID), real-time reversetranscription polymerase chain reaction (PCR), premature ventricular contraction (PVC), severe acute respiratory syndrome coronavirus 2 (SARS-CoV-2), United States (US), Vaccine Adverse Event Reporting System (VAERS)

Table of Contents Summary: Cases in the United States of symptomatic acute myocarditis in healthy adolescents following Pfizer-BioNTech COVID-19 vaccination.

Contributors' Statement Page

Drs Marshall and Guzman-Cottrill drafted the initial manuscript, designed the data collection instruments, collected data, participated in literature review, and reviewed and revised the manuscript.

Drs Jaggi and Lewis drafted case details for the initial manuscript, designed the data collection instruments, collected data, and reviewed and revised the manuscript.

Drs Collins, Ferguson Gagliardo, and Shaughnessy drafted case details for the initial manuscript, collected data, and reviewed and revised the manuscript.

Drs Corbin, Di Pentima, Emuren, Faherty, Fuss, Hall, Oster, Paintsil, Siddiqui, and Timchak reviewed clinical data, critically reviewed and revised the manuscript for important intellectual subject matter content.

Ms Caron participated in drafting the initial manuscript, data collection, and literature review.

All authors approved the final manuscript as submitted and agree to be accountable for all aspects of the work.

Abstract

Trials of coronavirus disease 2019 (COVID-19) vaccination included limited numbers of children so may not have detected rare but important adverse events in this population. We report seven cases of acute myocarditis or myopericarditis in healthy male adolescents who presented with chest pain all within four days after the second dose of Pfizer-BioNTech COVID-19 vaccination. Five patients had fever around the time of presentation. Acute COVID-19 was ruled out in all 7 cases based on negative severe acute respiratory syndrome coronavirus 2 (SARS-CoV-2) real-time reverse transcription polymerase chain reaction (PCR) tests of specimens obtained using nasopharyngeal swabs. None of the patients met criteria for multi-system inflammatory syndrome in children (MIS-C). Six of the 7 patients had negative SARS-CoV-2 nucleocapsid antibody assays, suggesting no prior infection. All patients had an elevated troponin. Cardiac magnetic resonance imaging (MRI) revealed late gadolinium enhancement characteristic of myocarditis. All 7 patients resolved their symptoms rapidly. Three patients were treated with non-steroidal anti-inflammatory drugs (NSAIDs) only and 4 received intravenous immune globulin (IVIG) and corticosteroids. This report provides a summary of each adolescent's clinical course and evaluation. No causal relationship between vaccine administration and myocarditis has been established. Continued monitoring and reporting to the Food and Drug Administration (FDA) Vaccine Adverse Event Reporting System (VAERS) is strongly recommended.

Case Report

Introduction

On December 11, 2020, the FDA issued an Emergency Use Authorization (EUA) for the Pfizer-BioNTech COVID-19 mRNA vaccine for prevention of COVID-19 for individuals 16 years of age and older.¹ On May 10, 2021, the FDA revised the EUA for this vaccine to include children 12 years and older¹. The Pfizer vaccine remains the only vaccine with an EUA for 12- to 17-year-old children. This vaccine demonstrated 94-95% efficacy in preventing COVID-19 infection in 16-55 year old participants, and 100% efficacy in the 12-15 year old age group^{1,2}. Systemic reactogenicity occurred more commonly in younger patients and after the second dose of vaccine¹.

Post-immunization myocarditis is a known rare adverse event following other vaccinations, particularly following smallpox vaccination³. Recently the news media has highlighted reports of myocarditis after COVID-19 mRNA vaccination involving United States (US) military patients and patients from Israel^{4,5}. The Israeli cohort identified a male predominance with an incidence of 1/20,000 (men aged 18 to 30 years old). However, a conclusive causal link to vaccination has not been confirmed at this time. Additionally, two recently published European case reports describe myocarditis after COVID-19 mRNA vaccination in a 56-year-old man with previous COVID-19 and a 39-year-old man with no history of COVID-19^{6,7}. This report summarizes case histories of 7 healthy male adolescents 14 to 19 years of age who developed acute myocarditis or myopericarditis within 4 days after receiving the second dose of the Pfizer-BioNTech COVID-19 vaccine, none of whom met criteria for MIS-C. All 7 patients were vaccinated in April and May of 2021 and have been reported to VAERS.

Patient 1

A previously well 16-year-old male presented to an emergency department (ED) with fatigue, poor appetite, fever of 38.3° C, and pain in the chest and both arms two days after his second Pfizer-BioNTech COVID-19 vaccine. He had no history of recent viral illness symptoms and no known COVID-19 exposures. Evaluation included an electrocardiogram (ECG) that showed atrioventricular dissociation with junctional escape and ST elevation and an elevated troponin I (2.59 ng/ml, normal range for this hospital, < 0.03 ng/mL). He was transferred to the Pediatric Intensive Care Unit of a tertiary care children's hospital for suspected myocarditis. Inflammatory markers were mildly elevated with D-dimer 1.52 ug/mL, erythrocyte sedimentation rate (ESR) of 43 mm/hr, and maximum C-reactive protein (CRP) of 12.3 mg/L (normal range, <1.0 mg/dL). Cardiac MRI demonstrated late gadolinium enhancement characteristic for myocarditis (Figure 1). Echocardiogram was normal. Troponin I peaked at 12.43 ng/mL (normal range for this hospital, <0.80 ng/mL) (Table 2). A nasopharyngeal swab for SARS-CoV-2 PCR was negative as was his serum SARS-CoV-2 nucleocapsid antibody. All other viral diagnostic studies were negative (Table 2). He remained well appearing, hemodynamically stable and in normal sinus rhythm throughout the six-day hospitalization. He received 100 grams (1.5 grams/kg) IVIG, then 10 mg/kg methylprednisolone intravenously on three consecutive days followed by a planned 12-week oral prednisone taper began. He also received 3 15-30 mg doses of intravenous ketorolac for pain. By 3 weeks after presentation, troponin had returned to normal.

Patient 2

A 19-year-old previously well male presented to a general ED with acute, persistent chest pain three days after his second Pfizer-BioNTech COVID-19 vaccine. He felt unwell for three days after vaccination with myalgias, fatigue, weakness, and subjective low-grade fevers. He had no

recent or remote history of viral illness, and no known COVID-19 exposures. ECG showed diffuse ST elevation consistent with acute myocardial injury or pericarditis. Urgent cardiac catheterization showed normal coronary arteries and normal left ventricular function. Initial high-sensitivity troponin T (232 ng/L, normal range, <14 ng/L) and CRP (6.7 mg/dL, normal range, <1.0 mg/dL) were highly elevated. Cardiac MRI confirmed myocarditis on the basis of the finding of patchy, mid-wall late gadolinium enhancement along the basal inferolateral wall segment. A nasopharyngeal swab for SARS-CoV-2 was negative. He remained hemodynamically stable and was discharged home two days later with the diagnosis of myopericarditis. He was treated with one 30 mg dose of intravenous ketorolac, 0.6 mg colchicine daily, and 650 mg aspirin three times daily.

One week later, he was seen in follow-up. He complained of mild fatigue, but had no chest pain or shortness of breath, and his ECG showed tachycardia with a heart rate of 105 beats per minute. ST segment resolution was noted. As a result of his sinus tachycardia, a 48-hour Holter monitor was done which showed an average heart rate of 83 beats per minute with a 1% premature ventricular contraction (PVC) burden. No other arrhythmias were noted. An echocardiogram was normal. The colchicine (0.6 mg) and aspirin (325 mg) daily were continued.

Patient 3

A 17-year-old previously well male presented with chest pain two days after his second Pfizer-BioNTech COVID-19 vaccine. Chest pain was worse when lying flat and was associated with left arm pain and paresthesias. He had no recent or remote history of viral illness, and no known COVID-19 exposures. ECG showed abnormal T waves with diffuse ST elevation consistent with pericarditis (Figure 2). Notable laboratory studies included elevated troponin I (5.550 ng/mL, normal range, <0.045 ng/mL), NT Pro-BNP (376 pg/mL, normal range, <100 pg/mL) and CRP

(25.3 mg/L, normal range, < 1.0 mg/dL). Echocardiogram showed normal function and coronaries, no effusion, trace mitral and aortic valve insufficiency, and decreased left ventricular basolateral and posterior regional strain. Cardiac MRI showed delayed enhancement at the left ventricular subepicardial basal anterolateral segment and basal to mid-ventricular inferolateral segments, consistent with myocardial necrosis. There was evidence of diffuse fibrosis on T1 weighted imaging and myocardial edema on T2 mapping. SARS-CoV-2 spike antibody was positive and nucleocapsid antibody was negative. Workup for other infections and a urine drug screen were negative. Troponin peaked at 12.200 ng/ml. His symptoms resolved with ibuprofen 600 mg orally every 6 hours and he was discharged at 48 hours. Based on the characteristics of his chest pain, ECG findings, and prompt response to anti-inflammatory medication, pericardial involvement was suspected. The presence of elevated cardiac markers and inflammation on cardiac MRI prompted the diagnosis of myopericarditis. At one-week follow-up, he remained asymptomatic with normal troponin, CRP, and ECG; the echocardiogram was unchanged.

Patient 4

An 18-year-old previously well male was admitted with a chief complaint of chest pain three days after he received the second dose Pfizer-BioNTech COVID-19 vaccine. Soon after vaccination, he had developed malaise, arthralgia, myalgia, and subjective fever. He had no recent or remote history of viral illness, and no known COVID-19 exposures. Two days prior to admission he noted mid-sternal chest pain and presented to his primary care physician who noted ST elevation on ECG prompting transfer to an ED, where evaluation showed elevated troponin T (1.09 ng/mL, normal range, <0.01 ng/mL), ST-elevation on ECG and normal echocardiogram. Cardiac MRI demonstrated edema, hyperemia, and fibrosis, consistent with myocarditis. A nasopharyngeal SARS-CoV-2 PCR was negative and antibody testing showed

positive spike and negative nucleocapsid antibodies for SARS-CoV-2. Troponin testing reduced over the course of the 3-day hospitalization and telemetry remained normal. He was treated with 70 grams IVIG and received 30 mg methylprednisolone intravenously every 12 hours for 2 doses followed by prednisone 30 mg orally twice daily with a gradual taper over 4 weeks. He also received ibuprofen 600 mg orally every 6 hours as needed for pain, and was discharged with a 30-day prescription for aspirin 81 mg orally once daily. At his first outpatient follow-up the following week, he felt well, troponin had normalized and both echocardiogram and ECG remained normal.

Patient 5

A 17-year-old previously well male was admitted with a chief complaint of chest pain. His symptoms began 3 days after his second Pfizer-BioNTech COVID-19 vaccine with sore throat, headache, dry cough and body aches. He had no recent or remote history of viral illness, and no known COVID-19 exposures. He then developed subjective fever and was treated for suspected streptococcal pharyngitis with amoxicillin; however, a throat swab yielded a negative streptococcal antigen test. The next day he developed midsternal chest pain that was worse when lying flat and radiated to the left arm. Evaluation in the ED showed elevated troponin T (3.21 ng/mL, normal range, <0.01 ng/mL), ST-elevation on ECG and normal function and structure on echocardiogram. Initial cardiac MRI demonstrated diffuse, nearly complete transmural LV free wall gadolinium enhancement. A nasopharyngeal SARS-CoV-2 PCR was negative; antibody testing showed positive spike and negative nucleocapsid antibodies for SARS-CoV-2. He received 70 grams IVIG and was started on methylprednisolone 30 mg intravenously every 12 hours (2 doses), then transitioned to prednisone 30mg orally every 12 hours with a gradual taper over 4 weeks. He also received ibuprofen 600 mg orally every 6 hours for the first 3 days and

then as needed. He was discharged home with a 30-day prescription for aspirin 81 mg by mouth once daily. Troponin level initially fell by 50% over the first 48 hours but on the third day of admission there was an acute rise that sustained for 12 hours before serial reduction. At discharge, the troponin T remained elevated (0.96 ng/mL, normal range, <0.01 ng/mL). Telemetry during the 5-day hospitalization showed occasional monomorphic PVCs and sinus bradycardia during sleep but was otherwise normal. Serial echocardiograms were normal. On follow-up 4 days after discharge, the echocardiogram was normal but ECG showed diffuse T wave abnormalities.

Patient 6

A 16-year-old previously well male was admitted with a chief complaint of chest pain. His initial symptoms began 3 days after the second Pfizer-BioNTech COVID-19 vaccine with malaise and subjective fever. He had no recent or remote history of viral illness, and no known COVID-19 exposures. The night prior to admission he developed acute midsternal chest pain that lasted for approximately 18 hours. Evaluation in the ED showed an elevated troponin T (0.66 ng/mL, normal range, <0.01 ng/mL), ST-elevation on ECG but normal function and structure on echocardiogram. Cardiac MRI demonstrated diffuse edema and subepicardial late gadolinium enhancement. A nasopharyngeal SARS-CoV-2 PCR was negative and antibody testing showed positive spike and negative nucleocapsid antibodies for SARS-CoV-2. He was treated with 70 grams IVIG and started on prednisone 30 mg orally twice daily with a gradual taper over 4 weeks. He did not receive any non-steroidal anti-inflammatory drugs (NSAID).

Troponin T climbed after admission and remained elevated throughout the hospitalization. Chest pain resolved after administration of 6 mg of morphine in the initial ED evaluation. Telemetry was normal throughout hospitalization. He was discharged 3 days after admission. He had not yet returned for follow-up visit at the time of this submission.

Patient 7

A 14-year-old previously well male presented to an urgent care clinic with pleuritic chest pain and shortness of breath two days after receiving his second Pfizer-BioNTech vaccine. A measured fever of 38.3° C began the day of vaccination. He had no recent or remote history of viral illness, and no known COVID-19 exposures. ECG showed ST segment elevation consistent with acute pericarditis. Additional evaluation included an echocardiogram which showed mildly depressed left and right ventricular systolic function and elevated troponin I (22.1 ng/mL, normal range, <0.045 ng/mL). His maximum temperature was 38.6° C on the day of admission. A nasopharyngeal SARS-CoV-2 PCR and serum nucleocapsid antibody were both negative. On hospital day 3, cardiac MRI showed areas with high T2 values indicating edema, T1 early post-contrast heterogeneity indicating hyperemia, and late gadolinium enhancement indicating myocardial fibrosis, all primarily in the subepicardial mid and apical left ventricle free wall. He was treated with NSAIDs (ketorolac 30 mg once, followed by naproxen 250 mg every 12 hours) and furosemide. Echocardiogram was improved one day after admission. He was discharged on hospital day 4 based on improvement of symptoms and ejection fraction; the troponin had declined to 8.02 ng/ml. His final diagnosis was myopericarditis. On follow-up 13 days later, he appeared well, but reported chest pain with exertion despite instructions to avoid strenuous exercise. An ECG showed non-specific T wave changes and echocardiogram was normal.

Discussion

We report 7 cases of clinical myocarditis or myopericarditis that developed in 14- to 19-year-old males within 4 days of receiving the second dose of the Pfizer-BioNTech COVID-19 vaccine with no evidence of acute SARS-CoV-2 infection and who did not fulfill criteria for MIS-C. Extensive diagnostic evaluation for other myocarditis etiologies was negative (Table 2), including respiratory pathogens from nasopharyngeal swabs, serum PCR tests, and infectious serologies. Additionally, all cardiac MRIs were diagnostic for myocarditis based on the modified Lake Louise criteria rather than MIS-C characteristics described by Blondiaux et al (diffuse myocardial edema without evidence of late gadolinium enhancement)^{8,9}. There was some suggestion of abnormal left ventricular myocardial echocardiographic strain corresponding to regions of myocardial necrosis on cardiac MRI (Patient 3).

All patients in this series had myocarditis or myopericarditis, which is the term for diagnosis of both myocardial and pericardial inflammation. These terms are often used interchangeably, which can make surveillance of these diseases challenging. Myocarditis and pericarditis are rare diseases. The true baseline incidence of myocarditis is unknown and varies by season, geography, and age: it has been reported to occur in 1.95/100,000 person-years in children <15 years of age in Finland and in 2.16 cases per 100,000 US military service members in a 30-day period¹⁰. It is more common in males, and among children demonstrates a bimodal incidence pattern, with peaks at <2 years of age and in adolescence¹¹. An evaluation for potential viral causes is recommended, although a cause is usually not found¹². There have been prior reports of myocarditis following smallpox vaccination¹⁰. In patients with myocarditis, restriction from competitive sports is recommended for at least 3 months until cleared by a cardiologist in order to avoid sudden cardiac events while the heart muscle recovers¹³. Less is known about the true incidence of pericarditis. Pericarditis can occur in the setting of a variety of infectious and

non-infectious illnesses¹⁴. In a study of patients ≥ 16 years of age in Finland, the incidence rate of hospitalizations for acute pericarditis was 3.32/100,000 person-years, with males at higher risk than females¹⁵ and in 2007, the incidence of acute pericarditis in one study was 27.2 cases per 100,000 per year¹⁶. Treatment for myocarditis and pericarditis may vary considerably depending on the patient characteristics, clinical condition, underlying cause, and physician preference. Consistent with a known male preponderance of myocarditis and pericarditis, all seven of our cases were male¹⁰.

The Pfizer-BioNTech clinical trials demonstrated an increased systemic reactogenicity and immunogenicity in younger study participants following mRNA vaccine¹. For example, 41.5% of adolescents developed chills after dose #2, compared to 35.1% of subjects 18-55 years of age¹. In terms of immunogenicity, an analysis of SARS-CoV-2 50% neutralizing titers 1 month after dose #2 demonstrated higher geometric mean titer (GMT) in children 12-15 years of age (GMT = 1,239.5), compared to subjects 16-25 years of age (GMT = 705.1)¹. Adverse events often occurred more frequently after dose #2 and within 2 days following vaccination and included injection site pain, fatigue, myalgia, chills, arthralgia, fever, injection site swelling or redness, nausea, malaise, and lymphadenopathy¹. It is possible that myocarditis or myopericarditis may be an additional rare adverse event related to systemic reactogenicity, but currently no causal association has been established between this vaccine and myopericarditis.

In our case series, 6 patients received non-steroidal anti-inflammatory drug (NSAID) treatment. Four patients received IVIG and oral prednisone; one of these four patients also initially received high-dose methylprednisolone (Table 2). The recognition of a possible temporal relationship of COVID-19 vaccine and myocarditis is critical, because the correct diagnosis may spare healthy adolescents and young adults presenting with chest pain and ECG ST elevation from undergoing unnecessary invasive medical procedures such as cardiac

catheterization. It is unclear if treatment with intravenous immunoglobulin and/or corticosteroids, in the absence of MIS-C criteria, is warranted with all cases of myocarditis that develop temporally after COVID-19 vaccination. Notably, 3 patients recovered with NSAID therapy alone.

Myocarditis and myopericarditis after COVID-19 vaccination appear rare. As of May 23, 2021, the Centers for Disease Control and Prevention (CDC) reports that 1,560,652 people <18 years of age have completed a two-dose series of COVID-19 vaccine¹⁷. Of these, 652,758 adolescents received their second dose more than fourteen days ago¹⁷. Currently, the Pfizer-BioNTech COVID-19 vaccine is the only COVID-19 vaccine authorized for children <18 years of age in the US. We urge physicians and healthcare providers to consider myocarditis in the evaluation of adolescents and young adults who develop chest pain after COVID-19 vaccination. All cases of myocarditis in patients with recent COVID-19 vaccination should be reported promptly to VAERS.

Our case series has inherent limitations. We compiled cases through personal communications between colleagues rather than using a systematic surveillance system to identify cases. It was not possible to exclude all alternative etiologies including idiopathic and other infectious etiologies, and there was not a systematic diagnostic evaluation for other viral etiologies. Cardiac biopsy was not performed on any patients, because they were all clinically stable during hospitalization. However, no patient had evidence of a preceding or concurrent symptomatic viral illness to implicate as an etiology of myocarditis, and the lack of eosinophilia dissuades a hypersensitivity reaction. The pathophysiology of myocarditis in these patients is indeterminate and we do not know if it is the same or different than classic myopericarditis or myopericarditis following other vaccines, associated with acute COVID-19, or MIS-C^{10,18-20}. Given the nature of a case series, we cannot determine the incidence rate of

myocarditis/myopericarditis following COVID-19 mRNA vaccination. Finally, a negative nucleocapsid antibody does not conclusively rule out the possibility of natural infection.

This report summarizes a series of US cases of myocarditis and myopericarditis following the Pfizer-BioNTech COVID-19 mRNA vaccine in adolescent males. All cases in this report occurred after the second vaccine dose. Fortunately, none of our patients was critically ill and each was discharged home. At present, there is no definite causal relationship between these cases and vaccine administration.

As of May 12, 2021, children in the US age 12 years and older are now eligible to receive the Pfizer-BioNTech vaccine. Primary care and ED physicians and healthcare providers should consider myocarditis as an etiology of chest pain in patients with recent COVID-19 mRNA vaccination. Elevated serum troponin, an abnormal ECG, and an abnormal cardiac MRI were seen in all cases (Table 1). An evaluation for acute COVID-19 infection (via PCR of respiratory tract sample) and past disease (via SARS-CoV-2 nucleocapsid and spike protein antibodies) is recommended for all cases of myocarditis that occur after COVID-19 mRNA vaccination, as well as a comprehensive workup to exclude other infectious and non-infectious causes. The benefits of vaccination significantly exceed possible risks. Individuals and physicians are encouraged to follow the guidance of the CDC Advisory Committee on Immunization Practices²¹. All cases of myocarditis with or without pericarditis occurring after COVID-19 vaccination should be promptly reported to VAERS.

Acknowledgments

We thank our patients and their families, who consented to sharing the details of their medical illnesses in this case report. We thank Katherine M. Mullin, MD who assisted with case finding.

References

1. Pfizer-BioNTech. Full Emergency Use Authorization (EUA) Prescribing Information, Revised 10 May 2021. <http://labeling.pfizer.com/ShowLabeling.aspx?id=14471&format=pdf&#page=13> Accessed May 15, 2021.
2. Polack FP, Thomas SJ, Kitchin N, et al. Safety and Efficacy of the BNT162b2 mRNA Covid-19 Vaccine. *N Engl J Med*. 2020;383(27):2603-2615.
3. Halsell JS, Riddle JR, Atwood E, et al. Myopericarditis following smallpox vaccination among vaccinia-naïve US military personnel. *JAMA*. 2003;289(24):3283-3289. doi:10.1001/jama.289.24.3283
4. Kime, P. Pentagon tracking 14 cases of heart inflammation in troops after COVID-19 shots. Military.com <https://www.military.com/daily-news/2021/04/26/pentagon-tracking-14-cases-of-heart-inflammation-troops-after-covid-19-shots.html> Published April 26, 2021. Accessed May 16, 2021.
5. Israel examining heart inflammation cases in people who received Pfizer COVID shot. Reuters. <https://www.reuters.com/world/middle-east/israel-examining-heart-inflammation-cases-people-who-received-pfizer-covid-shot-2021-04-25/> Published April 25, 2021. Accessed May 16, 2021.
6. Ammirati E, Cavalotti C, Milazzo A, et al. Temporal relation between second dose BNT162b2 mRNA Covid-19 vaccine and cardiac involvement in a patient with previous SARS-COV-2 infection. *IJC Heart Vasc*. 2021; 34 (2021) 100774. <https://doi.org/10.1016/j.ijcha.2021.100774>
7. Bautista Garcia J, Peña Ortega P, Bonilla Fernández JA et al. Acute myocarditis after administration of the BNT162b2 vaccine against COVID-19. *Rev Esp Cardiol*. 2021. <https://doi.org/10.1016/j.rec.2021.04.005>
8. Blondiaux E, Parisot P, Redheuil A, et al. Cardiac MRI in Children with Multisystem Inflammatory Syndrome Associated with COVID-19. *Radiology*. 2020;297(3):E283-E288.
9. Ferreira VM, Schulz-Menger J, Holmvang G, et al. Cardiovascular Magnetic Resonance in Nonischemic Myocardial Inflammation: Expert Recommendations. *J Am Coll Cardiol* 2018;72(24):3158–3176.
10. Arola A, Pikkarainen E, Sipila JO, Pykari J, Rautava P, Kyto V. Occurrence and Features of Childhood Myocarditis: A Nationwide Study in Finland. *J Am Heart Assoc*. 2017;6(11).
11. Ghelani SJ, Spaeder MC, Pastor W, Spurney CF, Klugman D. Demographics, trends, and outcomes in pediatric acute myocarditis in the United States, 2006 to 2011. *Circ*

- Cardiovasc Qual Outcomes*. 2012;5(5):622-627
12. Dasgupta A, Iannucci G, Mao C, et al. Myocarditis in the pediatric population: A review. *Congenital Heart Disease*. 2019; 14(5):868-877. <https://doi.org/10.1111/chd.12835>
 13. Maron BJ, Udelson JE, Bonow RO, Nishimura RA, Ackerman MJ, Estes NAM, 3rd, et al. Eligibility and Disqualification Recommendations for Competitive Athletes With Cardiovascular Abnormalities: Task Force 3: Hypertrophic Cardiomyopathy, Arrhythmogenic Right Ventricular Cardiomyopathy and Other Cardiomyopathies, and Myocarditis: A Scientific Statement From the American Heart Association and American College of Cardiology. *J Am Coll Cardiol*. 2015;66(21):2362-2371.
 14. Adler Y, Charron P, Imazio M, Badano L, Baron-Esquivias G, Bogaert J, et al. 2015 ESC Guidelines for the diagnosis and management of pericardial diseases: The Task Force for the Diagnosis and Management of Pericardial Diseases of the European Society of Cardiology (ESC) Endorsed by: The European Association for Cardio-Thoracic Surgery (EACTS). *Eur Heart J*. 2015;36(42):2921-2964.
 15. Kyto V, Sipila J, Rautava P. Clinical profile and influences on outcomes in patients hospitalized for acute pericarditis. *Circulation*. 2014;130(18):1601-1606
 16. Imazio M, Cecchi E, Demichelis B, Chinaglia A, Ierna S, Demarie D, et al. Myopericarditis versus viral or idiopathic acute pericarditis. *Heart*. 2008 Apr;94(4):498-501.
 17. Demographic Characteristics of People Receiving COVID-19 Vaccinations in the United States. Centers for Disease Control and Prevention website. <https://covid.cdc.gov/covid-data-tracker/#vaccination-demographic> Published May 23, 2021. Accessed May 23, 2021.
 18. Arness MK, Eckart RE, Love SS, Atwood JE, Wells TS, Engler RJ, et al. Myopericarditis following smallpox vaccination. *Am J Epidemiol*. 2004;160(7):642-651.
 19. Kawakami R, Sakamoto A, Kawai K, Gianatti A, Pellegrini D, Nasr A, et al. Pathological Evidence for SARS-CoV-2 as a Cause of Myocarditis: JACC Review Topic of the Week. *J Am Coll Cardiol*. 2021;77(3):314-325.
 20. Vukomanovic VA, Krasic S, Prijic S, Ninic S, Minic P, Petrovic G, et al. Differences Between Pediatric Acute Myocarditis Related and Unrelated to SARS-CoV-2. *Pediatr Infect Dis J*. 2021;40(5):e173-e178.
 21. Vaccine Recommendations and Guidelines of the ACIP. Centers for Disease Control and Prevention website.

Table 1. Demographic and clinical characteristics of seven cases of symptomatic myocarditis after dose #2 of Pfizer-BioNTech COVID-19 vaccine

	Patient 1	Patient 2	Patient 3	Patient 4	Patient 5	Patient 6	Patient 7
Age (years)	16	19	17	18	17	16	14
Sex	Male	Male	Male	Male	Male	Male	Male
Race/Ethnicity	White	White	White	White	Latino	White	White
Weight (kg)	68	68	71	69	64	71	92
BMI (kg/m²)	24	19	21	21	19	22	28
Exposure to COVID-19 in 14 days prior to illness onset	None	None	None	None	None	None	None
Time between vaccine dose #2 and symptom onset (days)	2	3	2	2	4	3	2
Total hospital LOS (days)	6	2	2	4	5	3	4
ICU LOS (days)	4	None	None	4	5	2	2
Symptoms Upon Presentation							
Chest pain	Present	Present	Present	Present	Present	Present	Present
Other pain	Bilateral arm pain	Myalgias	Bilateral arm pain, numbness, paresthesia	--	Bilateral arm pain, abdominal pain	--	--
Fever	38.3° C by history	Subjective, chills	--	Subjective	Subjective	--	38.3° C by history
Fatigue	Present	Present	--	Present	--	--	--
Other	Nausea, vomiting, anorexia, headache	Weakness	--	Nausea	Nausea, vomiting, anorexia, SOB, palpitations	SOB	SOB

--:Not present; Kg: kilograms, BMI: Body Mass Index, LOS: Length of Stay; ICU: Intensive Care Unit; SOB: Shortness of breath.

Prepublication Release

Table 2. Summary of diagnostics and therapeutics: seven cases of symptomatic myocarditis after dose #2 of Pfizer-BioNTech COVID-19 vaccine

	Patient 1	Patient 2	Patient 3	Patient 4	Patient 5	Patient 6	Patient 7
Laboratory Findings on Admission							
Troponin (ng/mL) (normal range)	Troponin I: 2.59 (<0.03)	High-sensitivity troponin T: 232 (< 14)	Troponin I: 5.55 (<0.045)	Troponin T: 1.09 (<0.01)	Troponin T: 3.2 (<0.01)	Troponin T: 0.66 (<0.01)	Troponin I: 22.1 (<0.045)
Brain natriuretic peptide (pg/mL) (normal < 100)	--	--	--	--	--	--	107.9
NT pro-BNP (pg/mL) (normal < 125)	428	--	376	--	978	149	--
Peripheral white blood cell count (thousand/cu mm)	6.97	8.69	11.8	12.6	16.3	5.0	8.11
Absolute lymphocyte count (thousand/cu mm)	1.69	1.39	2.13	2.3	4.1	1.4	1.05
Absolute neutrophil count (thousand/cu mm)	4.65	5.93	7.46	9.5	9.8	2.8	4.73
Platelet count (thousand/cu mm)	198	208	231	236	297	189	208
Albumin (g/dL)	3.9	4.1	4.1	4.4	4.0	3.8	3.5
Aspartate transaminase (units/L)	54	29	41	82	150	59	87
Alanine transaminase (units/L)	30	14	33	20	46	22	38
Ferritin (ug/L)	70	--	90	103	347	65	84

Prepublication Release

C-reactive protein (mg/dL) (normal < 1.0)	0.99	6.7	2.5	12.7	18.1	1.5	7.7
Erythrocyte sedimentation rate (mm/hr)	18	13	6	40	38	3	10
Prothrombin time (seconds)	--	--	14.0	--	12.1	11.4	14.8
Partial thromboplastin time (seconds)	22.3	--	31.4	--	30.4	27.9	35.6
International Normalized Ratio INR	1.11	--	1.06	--	1.13	1.06	1.2
Other Pertinent Laboratory Findings							
Highest troponin (ng/mL) (normal range)	Troponin I: 12.43 (<0.80)	High sensitivity Troponin T: 388 (<14)	Troponin I: 12.20 (<0.045)	Troponin T: 1.09 (<0.01)	Troponin T: 3.33 (<0.01)	Troponin T: 0.82 (<0.01)	Troponin I: 22.1 (<0.045)
Lowest troponin prior to discharge (ng/mL) (normal range)	Troponin I: 1.42 (<0.80)	--	Troponin I: 5.79 (<0.045)	Troponin T: 0.4 (<0.01)	Troponin T: 0.96 (<0.01)	Troponin T: 0.01 (<0.01)	Troponin I: 8.02 (<0.045)
Highest BNP (normal range)	--	--	--	--	--	--	205 pcg/mL (<100)
Highest NT-pro BNP (normal range)	482 pg/mL (<125)	--	376 pg/mL (<300)	--	978 pcg/mL (<125)	275 pcg/mL (<125)	--
Highest C-reactive protein (mg/dL) (normal < 1.0)	1.23	6.7	2.53	12.7	18.1	1.8	12.7
COVID-19 PCR	Negative	Negative	Negative	Negative	Negative	Negative	Negative
COVID-19 spike antibody (Manufacturer)	--	--	Positive (Roche)	Positive (Roche)	Positive (Roche)	Positive (Roche)	--
COVID-19 nucleocapsid antibody (Manufacturer)	Negative (Abbott)	--	Negative (Roche)	Negative (Roche)	Negative (Roche)	Negative (Roche)	Negative (Abbott)

Prepublication Release

Respiratory pathogen panel PCR* (Manufacturer)	Negative (BioFire)	Negative (BioFire)	Negative (BioFire)	Negative (BioFire)	Negative (BioFire)	Negative (BioFire)	Negative (BioFire)
Adenovirus diagnostics	Negative serum PCR	--	Negative serology	Negative serum PCR	Negative serum PCR	--	Negative serum PCR
Enterovirus diagnostics	Negative serum PCR	--	Negative serology	Negative serum PCR	Negative serum PCR	Negative serum PCR	Negative serum PCR
Cytomegalovirus diagnostics	Negative serum PCR	--	Negative serology	Negative serum PCR	Negative serum PCR	Negative serum PCR	Negative serology
Epstein-Barr virus diagnostics	--	--	Negative serology	Negative serum PCR	Negative serum PCR	Negative IgM, positive IgG antibody	Negative serology
Other diagnostics	--	--	Negative Parvovirus, Bartonella, and Lyme serology, negative urine drug screen	--	Negative Parvovirus and Bartonella serology, negative HHV-6 serum PCR	Negative Lyme serology, negative <i>Mycoplasma</i> serum PCR, negative Parvovirus serum PCR	Negative Parvovirus IgM, positive Parvovirus IgG antibody, negative <i>Mycoplasma</i> PCR (throat swab)
Diagnostic Imaging Findings							
Cardiac MRI	LGE (subepicardial) involving lateral LV apex, myocardial edema of lateral LV wall, left axillary adenopathy	LGE involving mid LV wall, myocardial edema of basal inferolateral LV wall	LGE (subepicardial) involving basal anterolateral and basal to mid-ventricular inferolateral LV segments, myocardial edema, elevated extracellular volume fraction (29.2%)	Fibrosis, myocardial edema, hyperemia, mild mitral regurgitation (RF ~18%)	LGE (epicardial) involving anterior and lateral LV wall, no myocardial edema	LGE, diffuse myocardial edema	LGE (subepicardial) involving mid and apical LV free wall, myocardial edema, hyperemia

Prepublication Release

Echocardiogram	Normal	Normal	Borderline basal lateral and basal posterior strain	Normal	Normal	Normal	Mildly depressed RV and LV systolic function (LVEF 47%)
Electrocardiogram	Atrioventricular dissociation with junctional escape rhythm, ST elevation	ST segment elevation (diffuse)	ST elevation (diffuse), T wave abnormality	ST elevation	Sinus bradycardia, T wave abnormality	ST elevation (diffuse)	ST elevation, low voltage of extremity leads
Therapeutics							
Oxygen supplementation	None	None	None	None	None	None	LFNC
Vasoactive medications or inotropic support	None	None	None	None	None	None	None
Anti-inflammatory agents and other relevant medications	NSAID, IVIG, IV methylprednisolone, PO prednisone, famotidine	NSAID, colchicine, aspirin	NSAID, famotidine	NSAID, IVIG, IV methylprednisolone, PO prednisone	NSAID, IVIG, IV methylprednisolone, PO prednisone, aspirin	IVIG, PO prednisone	NSAID, famotidine, furosemide

--:Not done; LGE: late gadolinium enhancement; LV: Left ventricular; RV: Right ventricular, LVEF: Left ventricular ejection fraction; LFNC: Low flow nasal cannula; NSAID: Non-steroidal anti-inflammatory drug; IVIG: Intravenous immunoglobulin; IV: intravenous; PO: *per os* (oral); q12hr: every 12 hours; HHV-6: Human herpesvirus-6

* Footnote: BioFire Respiratory Panel includes PCR for Adenovirus, Coronavirus 229E, Coronavirus HKU1, Coronavirus NL63, Coronavirus OC43, Metapneumovirus (human), Rhinovirus/Enterovirus, Influenza A, Influenza B, Parainfluenza 1, Parainfluenza 2, Parainfluenza 3, Parainfluenza 4, Respiratory Syncytial Virus, *Bordetella parapertussis*, *Bordetella pertussis*, *Chlamydomphila pneumonia*, *Mycoplasma pneumonia*.

Figure 1: Cardiac magnetic resonance imaging (MRI) of Patient 1. Four chamber (a) and short axis (b) post-contrast images depicting apical and mid-chamber lateral wall sub-epicardial late gadolinium enhancement (arrows). Pattern and distribution is highly characteristic for myocarditis.

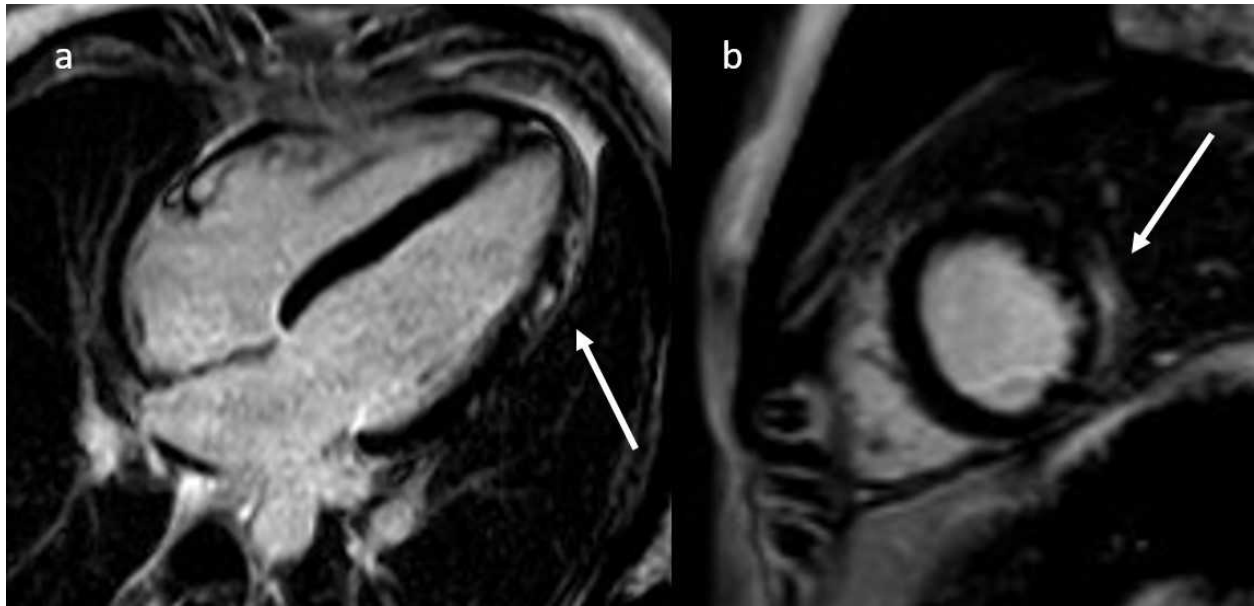
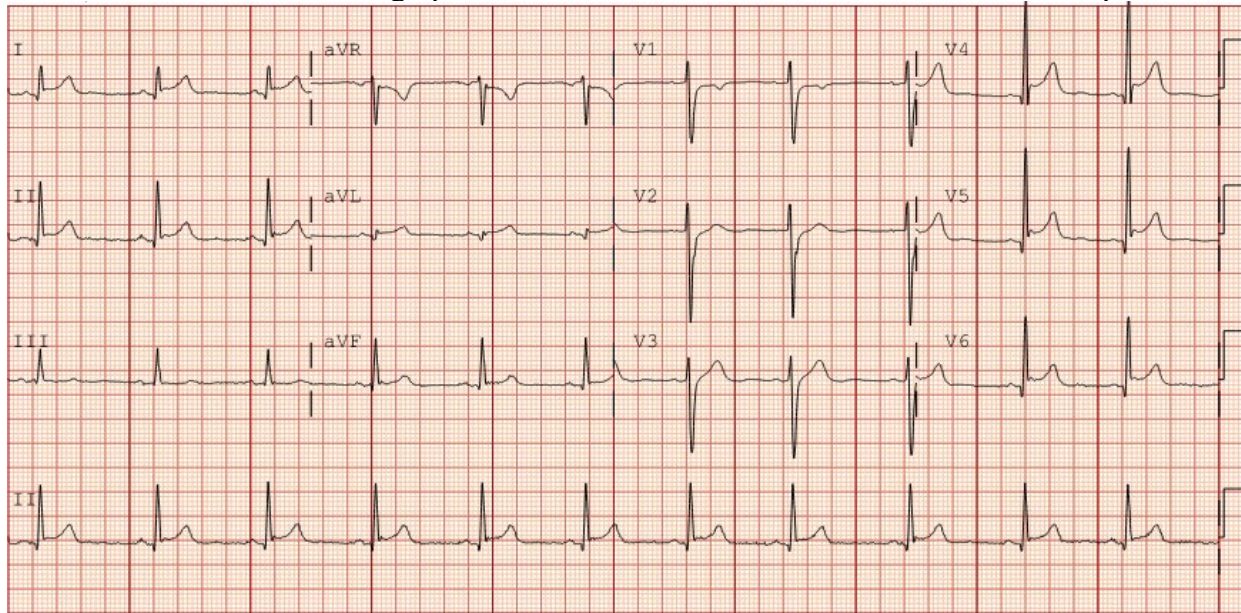


Figure 2:

Patient 3 electrocardiograph with diffuse ST elevations seen, characteristic of pericarditis.



Symptomatic Acute Myocarditis in Seven Adolescents Following Pfizer-BioNTech COVID-19 Vaccination

Mayme Marshall, Ian D. Ferguson, Paul Lewis, Preeti Jaggi, Christina Gagliardo, James Stewart Collins, Robin Shaughnessya, Rachel Carona, Cristina Fuss, Kathleen Jo E. Corbin, Leonard Emuren, Erin Faherty, E. Kevin Hall, Cecilia Di Pentima, Matthew E. Oster, Elijah Paintsil, Saira Siddiqui, Donna M. Timchak and Judith A. Guzman-Cottrill

Pediatrics originally published online June 4, 2021; originally published online June 4, 2021;

Updated Information & Services

including high resolution figures, can be found at:
<http://pediatrics.aappublications.org/content/early/2021/06/04/peds.2021-052478.citation>

Permissions & Licensing

Information about reproducing this article in parts (figures, tables) or in its entirety can be found online at:
<http://www.aappublications.org/site/misc/Permissions.xhtml>

Reprints

Information about ordering reprints can be found online:
<http://www.aappublications.org/site/misc/reprints.xhtml>

American Academy of Pediatrics

DEDICATED TO THE HEALTH OF ALL CHILDREN®



PEDIATRICS[®]

OFFICIAL JOURNAL OF THE AMERICAN ACADEMY OF PEDIATRICS

Symptomatic Acute Myocarditis in Seven Adolescents Following Pfizer-BioNTech COVID-19 Vaccination

Mayme Marshall, Ian D. Ferguson, Paul Lewis, Preeti Jaggi, Christina Gagliardo, James Stewart Collins, Robin Shaughnessy, Rachel Carona, Cristina Fuss, Kathleen Jo E. Corbin, Leonard Emuren, Erin Faherty, E. Kevin Hall, Cecilia Di Pentima, Matthew E. Oster, Elijah Paintsil, Saira Siddiqui, Donna M. Timchak and Judith A. Guzman-Cottrill

Pediatrics originally published online June 4, 2021; originally published online June 4, 2021;

The online version of this article, along with updated information and services, is located on the World Wide Web at:

<http://pediatrics.aappublications.org/content/early/2021/06/04/peds.2021-052478.citation>

Pediatrics is the official journal of the American Academy of Pediatrics. A monthly publication, it has been published continuously since 1948. Pediatrics is owned, published, and trademarked by the American Academy of Pediatrics, 345 Park Avenue, Itasca, Illinois, 60143. Copyright © 2021 by the American Academy of Pediatrics. All rights reserved. Print ISSN: 1073-0397.

American Academy of Pediatrics

DEDICATED TO THE HEALTH OF ALL CHILDREN[®]

